

# A Retrospective Cephalometric Evaluation on Location of Center of Mandibular Autorotation after Le Fort I Superior Repositioning Osteotomy

**T. Hosseinzadeh Nik**

Professor, Dental research center, Dentistry research institute, Tehran University of Medical Sciences, Tehran, Iran And Department of Orthodontics, Faculty of Dentistry, Tehran University of Medical Sciences, Tehran, Iran

**E. Sadat Emdadian Razavi**

Postgraduate student, Orthodontic department, Dental school, Tehran University of Medical Sciences

**A. Modarresi**

Postgraduate student, Oral and maxillofacial surgery department, Dental school, Azad University of Medical Sciences

**M. Mollaei**

Postgraduate student, Orthodontic department, Dental school, Azad University of Medical Sciences

## Abstract

**Introduction** A possible treatment option for non-growing patients with vertical maxillary excess (VME), is superior repositioning of maxilla with or without mandibular surgery. After maxillary impaction, mandible rotates around a center. A common assumption at the time of cephalometric prediction, is taking condyle as an unchangeable center of rotation. Any error in determination of center of mandibular autorotation (CMA) may lead to improper jaw positioning and unaesthetic results. **Materials and methods:** In this study, before and after cephalometric radiographs from fourteen orthognathic patients with maxillary impaction were evaluated. **Results** showed that center of mandibular autorotation are not similar in different patients, partly because of individualized craniofacial morphology. Therefore, precise determination of center of mandibular autorotation is necessary for obtaining ideal results.

## Key words:

Le Fort I, Superior repositioning, mandibular autorotation, center of rotation

**Correspondent:** E.Sadat emdadian Razavi

Postgraduate student, Orthodontic department, Dental school, Tehran University of Medical Sciences

## Introduction

Patients with vertical maxillary excess, almost have some certain features like greater anterior facial height, shorter ramus height, larger gonial angle, a more retrognathic mandible, and steeper mandibular occlusal plane than normal population. In these patients, transverse dimension is also affected and both maxillary and mandibular intermolar widths are narrower than normal subjects [1].

Treatment of this condition, which also called “hyperdivergent skeletal pattern,” or “skeletal openbite,” is superior repositioning of maxilla concomitant with mandibular autorotation, or double jaw surgery including maxillary superior repositioning and mandibular advancement or set back. Deciding to perform one jaw or two jaws surgery depends on cephalometric prediction [2]. The common cephalometric prediction in clinical practice is rotating the mandible around a point at center of the condyle, with assumption that mandible always rotates around this point for establishing a new vertical dimension [2-10].

The center of rotation is a point that a body rotates around it and moves from one position to another. Several CMAs have been suggested in the literature. Fish and Epker used top of mandibular condylar head [11]. Sperry et al., suggested mastoid region for cephalometric prediction [3]. Bryan and Hunt compared these three points for presurgical prediction of mandibular autorotation: center of the condyle, the condylion, and Sperry’s mastoid point. The later was the least inaccurate one [12].

The importance of precise determination of mandibular autorotation has been investigated [3, 10]. Any error in reproducing the CMA can result in occlusal and skeletal disharmony after removing surgical splints and lead to patient and clinician dissatisfaction with the results [8].

Accurate determination of CMA allows prediction of the sagittal position of maxilla and some changes in the midface after maxillary impaction. At the time of

surgery, the mandible does not always autorotate to its predicted position. This problem may result in increased operating time and/or orthodontic finishing time and difficulty.

The aim of this retrospective study is to evaluate CMA in patients undergoing maxillary impaction and analysis the postsurgical soft tissue landmarks.

## Material & Methods

Records obtained from 14 patients who had undergone LeFort I osteotomies with superior repositioning of the maxilla.

The subjects had been treated at Tehran University of Medical Sciences, Shariati hospital. Type of operation that was performed for each patient is presented in Table (1). All the patients were non-growing and none of them had mandibular surgery. For all subjects, clear presurgical, and postsurgical cephalometric radiographs with same scale and magnification and with the teeth in occlusion wire available. The radiographs were traced and the S-N line, the maxilla (including first molar and central incisor), and the mandible (including internal border of the symphysis) were recorded. Sella-nasion, occlusal, palatal and mandibular reference lines were drawn. These reference lines were established on the tracing of the presurgical cephalometric radiograph. They were transferred to subsequent radiographs by superimposing onto the postsurgical films.

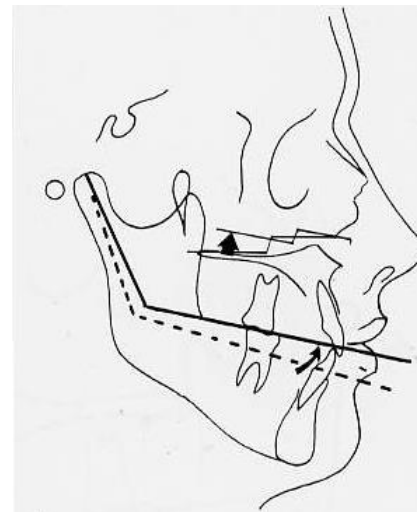
Presurgical and Postsurgical lateral cephalograms were superimposed on S-N plane on S point. Three horizontal reference planes, Palatal, mandibular and occlusal, were assessed.

Based on method described by Rouleaux [13], the center of rotation determined (Figure (1)). With this method, any two landmarks are selected. The location of these two landmarks is identified in the pretreatment position and then again after the rotation has occurred. A line is drawn between the pretreatment and rotated positions. The perpendicular bisector to each of these lines is constructed. The intersection of the two bisectors is defined as the center of rotation.

**Table 1.** Type of surgery of subjects in the study

Case number	Lefort I impaction	Genioplasty
Case 1	A*2	N*
	P*2	
Case 2	A 2	Y*
	P 4	
Case 3	A 1	Y
	P 3	
Case 4	A 4	N
	P 4	
Case 5	A 4	N
	P 4	
Case 6	A 5	Y
	P 5	
Case 7	A 0	N
	P 3	
Case 8	A 4	N
	P 4	
Case 9	A 2	N
	P 2	
Case 10	A 3	N
	P 4	
Case 11	A 2	N
	P 2	
Case 12	A 3	Y
	P 3	
Case 13	A 1	Y
	P 3	
Case 14	A 5	Y
	P 5	

\*A=Anterior, P=Posterior, N=No, Y=Yes



**Figure 2.** Center of mandibular autorotation

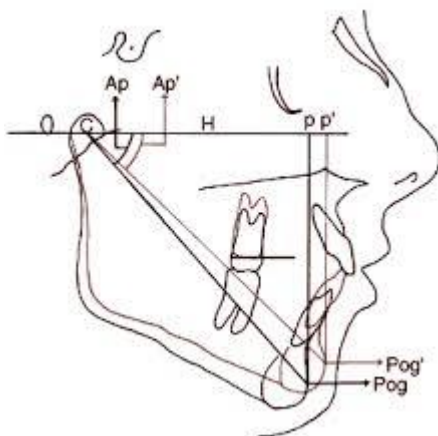
### Results

Based on the results found from cephalometric superimpositions, the center of rotation of occlusal plane in cases with parallel impaction was at more posterior point than differential maxillary impaction. The more the difference between amount of anterior and posterior maxillary impactions, the more anteriorly the center of rotation; and usually, this differential impaction means that amount of posterior impaction is more than anterior.

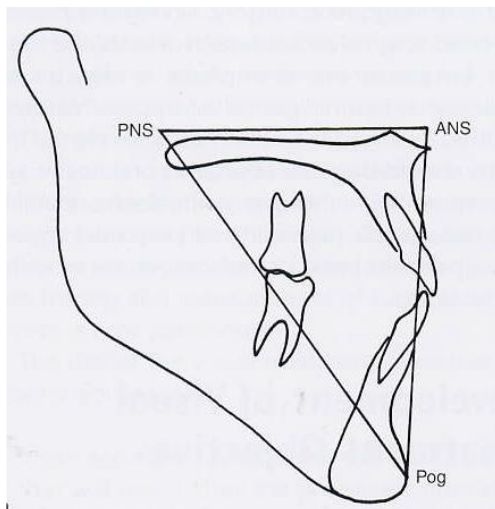
The center of rotation of mandible, during its autorotation, followed the same pattern as palatal plan; which means that in the cases with differential impaction, the center of rotation shifted anteriorly.

The centers of rotation of two other planes were different, sometimes posterior, sometimes at the middle point of the plane and in one case at the anterior point.

As shown in Figure (1), when the point of intersection displaces, the center of rotation will not be the same. As like as what Reyneke did [14], we draw a triangle with these three points: ANS, PNS and Pog (Figure (3)). In this triangle, we saw that the angle between horizontal and vertical legs ( $\alpha$ ), changes differently in different pre and post radiographies.



**Figure 1.** Changes in occlusal plane



**Figure 3.** Triangle drawn by Reyneke

## Discussion

Traditional management of double jaws surgery either maintains the presurgical occlusal plane angulation or selectively increases the occlusal plane relative to Frankfort Horizontal plane after changing vertical position of maxilla. Although these methods may achieve an acceptable interrelation of the teeth in centric relation, they may not provide the optimal functional and esthetic relationship of dentition and musculoskeletal structures [14, 15].

Also in one jaw surgery, the occlusion is important, in mandibular setback or advancement, horizontal movement of the mandible depends on the maxillary occlusal plane [14].

In superior or inferior repositioning of maxilla, final occlusal plane is determined by mandibular occlusal plane after its autorotation that occurs both clockwise and counterclockwise at superior posterior point of condyle [16].

Conventional orthognathic surgery (especially in high or low inclination of occlusal plane) may not lead to ideal esthetic results.

This may be due to we always take the superior-posterior point of condyle as the center of rotation in cases that require maxillary superior repositioning surgery. Taking this point as a constant CMA in cephalometric prediction or model surgery is erroneous. As Nattestad A. et al., stated [9], an error in localization of CMA may lead unsatisfactory esthetic results. In details, the found that

“the effect of an erroneous determination of the true center of mandibular rotation will be particular evident in the correction of dentofacial deformities where a major autorotation of the mandible is necessary. But even a mandibular rotation of 5 mm measured at the incisors, can produce a 2 mm horizontal malpositioning of the maxilla, if there is a difference of 20 mm between the presumed center of mandibular rotation and the true center, the horizontal malpositioning will increase to 3 mm if the size of the open bite is 9.5 mm.”

In our study, treatment plans that include maxillary differential impaction do not have CMAs similar to maxillary total impaction. Differential impaction of the maxilla is more indicated in long face/open bite cases. In these cases, posterior of the maxilla is more impacted. After impaction, the mandible rotates around a center.

Total impaction of maxilla is more indicated in VME cases which gummy smile is also presents.

We found that in total impaction cases, the CMA is located at a point posterior to condyle or even at mastoid region; but in differential impaction cases, the CMA moves forward from condyles. In these cases, as the differential amount of impaction increases, the CMA positions more anterior from condyles. Figure (4). illustrated CMAs found in this study. Anterior points dominantly related to differential impactions.

In two jaws surgery cases, final horizontal and vertical relation between ANS, maxillary incisors and Pog are the esthetic key factors.

Horizontal and vertical relations between these three points, determine horizontal and vertical skeletal and dental relationships respectively.

In horizontal dimension, ANS indicate anteroposterior maxillary deficiency or excess, incisor–lip relationship indicate dental protrusion or retrusion, increased overjet or reverse jet and position of pogonion indicate microgenia , macrogenia, and deficiency or excess in mandibular anteroposterior position [14].

Soft tissue harmony between subnasal, upper, and lower lip support and position of soft tissue Pog are affected by dental and skeletal structures.

For observation of treatment options in two jaws surgery cases, soft and hard tissue changes that are independent

of the present occlusal plane, Reyneke designed a triangle. We used a same triangle in this study. As previously stated, we take an angle for determining lower facial one third changes.

When changes of  $\alpha$  angle were minimal, two occlusal plane lines were come together more posteriorly and vice versa. Minimal changes in  $\alpha$  angle shows minimal changes in the patient's profile also; because different amounts of  $\alpha$  angle show different proportions between legs, which determine height, and direction of lower anterior facial of profile view.

When  $\alpha$  angle did not change considerably, the mandibular plane moved parallel to the previous line. In the theoretical words the center of rotation is at the infinity, but when  $\alpha$  angle changed a large amount, the horizontal reference lines (mandibular and palatal planes), converge near the ramus: not so far posteriorly. Interestingly, cases in which  $\alpha$  angle changed considerably were ones, which ramus height was short and gonial angle was obtuse; i.e., Long face cases. In these cases, the dominant treatment plan was maxillary differential impaction. The other group was cases with two jaws surgery include differential maxillary impaction and mandibular set back. This group excluded because of mandibular surgery, but changes of  $\alpha$  angle were the most. As a conclusion we can say in more severe sagittal and vertical discrepancies, we saw more changes of  $\alpha$  angle and more anterior the CMA, and vice versa.

These are additional factors that can have influence on the MAC, like anatomic considerations and skill of surgeons. For example in Figure (5), superimposition of presurgical and postsurgical lateral cephalometries of two patients are illustrated. The treatment plane for both of them was Le Fort I total superior repositioning osteotomy; but due to different factors, the CMA is not a same.

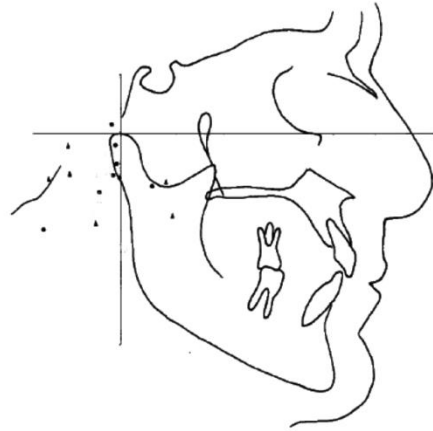


Figure 4. Centers of mandibular autorotation in the subjects

The main factor, which determines direction of rotation and center of rotation, is esthetic requirement of each patient; but prediction of postsurgical profile is not completely accurate. According to Rekow D. et al., there is great variation in the location of center of autorotation of the mandible after the maxillary superior repositioning surgery [17]. The results of Nattestad A., and Vedtofte P. study showed that a large inter-individual variation is existed in the position of the CMA which it is suggested can be caused by differences in craniofacial morphology [7]. Kolokitha O. and Chatzistavrou E. are also stated that additional to technical problems related to prediction method, some biological factors can affect the post-surgical results. The most important ones are relapse and CMA that both are individual factors [18].

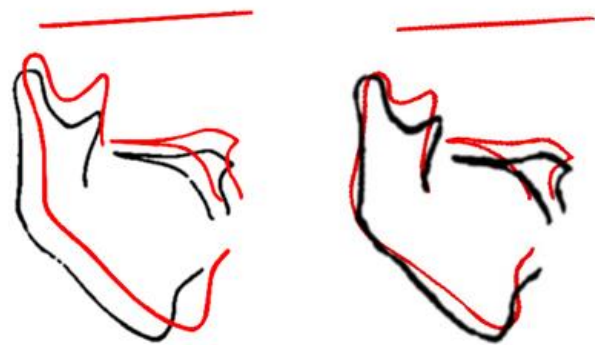


Figure 5. Presurgical and postsurgical lateral cephalometry superimpositions

## Conclusion

The present study agrees the hypothesis that a CMA outside the condylar body can exist. Individual variations was found in the position of the CMA, which may be caused by individual differences in the craniofacial morphology as suggested by Nattestad A. and Vedtofte P [7].

Variation in the CMA can be a source of variation between final soft and hard tissue characteristics of the face. We use the concept of the triangle in our study to show that in traditional orthognathic surgery, the CMA can be different. So considering condyles as a definite CMA is a fault.

## References

1. Buschang, P.H., H. Jacob, and R. Carrillo. *The Morphological Characteristics, Growth, and Etiology of the Hyperdivergent Phenotype*. in *Seminars in Orthodontics*. 2013. Elsevier.
2. Wang, Y.-C., et al., *The inter-relationship between mandibular autorotation and maxillary LeFort I impaction osteotomies*. *Journal of Craniofacial Surgery*, 2006. **17**(5): p. 898-904.
3. Sperry, T.P., M.J. Steinberg, and B.J. Gans, *Mandibular movement during autorotation as a result of maxillary impaction surgery*. *American journal of orthodontics*, 1982. **81**(2): p. 116-123.
4. Radney, L.J. and J.D. Jacobs, *Soft-tissue changes associated with surgical total maxillary intrusion*. *American journal of orthodontics*, 1981. **80**(2): p. 191-212.
5. Mansour, S., C. Burstone, and H. Legan, *An evaluation of soft-tissue changes resulting from Le Fort I maxillary surgery*. *American journal of orthodontics*, 1983. **84**(1): p. 37-47.
6. Rosen, H.M., *Occlusal plane rotation: aesthetic enhancement in mandibular micrognathia*. *Plastic and reconstructive surgery*, 1993. **91**(7): p. 1231-1240.
7. Nattestad, A. and P. Vedtofte, *Mandibular autorotation in orthognathic surgery: a new method of locating the centre of mandibular rotation and determining its consequence in orthognathic surgery*. *Journal of Cranio-Maxillofacial Surgery*, 1992. **20**(4): p. 163-170.
8. Nadjmi, N., et al., *Prediction of mandibular autorotation*. *Journal of oral and maxillofacial surgery*, 1998. **56**(11): p. 1241-1247.
9. Nattestad, A., P. Vedtofte, and E. Mosekilde, *The significance of an erroneous recording of the centre of mandibular rotation in orthognathic surgery*. *Journal of Cranio-Maxillofacial Surgery*, 1991. **19**(6): p. 254-259.
10. Rekow, E.D., et al., *Treatment-induced errors in occlusion following orthognathic surgery*. *American journal of orthodontics*, 1985. **88**(5): p. 425-432.
11. Fish, L. and B. Epker, *Surgical-orthodontic cephalometric prediction tracing*. *Journal of clinical orthodontics: JCO*, 1980. **14**(1): p. 36.
12. Bryan, D. and N. Hunt, *Surgical accuracy in orthognathic surgery*. *British Journal of Oral and Maxillofacial Surgery*, 1993. **31**(6): p. 343-349.
13. Rouleaux, F., *The kinematics of machinery: outline of a theory of machines (translated by ABW Kennedy)*. 1875, Dover.
14. Reyneke, J.P., *Essentials of orthognathic surgery*. 2003: Quintessence Publishing Company.
15. Wolford, L.M., P.D. Chemello, and F. Hilliard, *Occlusal plane alteration in orthognathic surgery—Part I: Effects on function and esthetics*. *American Journal of Orthodontics and Dentofacial Orthopedics*, 1994. **106**(3): p. 304-316.
16. Sonego, C., et al., *Aesthetic and functional implications following rotation of the maxillomandibular complex in orthognathic surgery: a systematic review*. *International journal of oral and maxillofacial surgery*, 2014. **43**(1): p. 40-45.
17. Rekow, E.D., T.M. Speidel, and R.A. Koenig, *Location of the mandibular center of autorotation in maxillary impaction surgery*. *American Journal of Orthodontics and Dentofacial Orthopedics*, 1993. **103**(6): p. 530-536.
18. Kolokitha, O.-E. and E. Chatzistavrou, *Factors influencing the accuracy of cephalometric prediction of soft tissue profile changes following orthognathic surgery*. *Journal of maxillofacial and oral surgery*, 2012. **11**(1): p. 82-90.