

Effectiveness and complications of ^{188}Re -HEDP in palliative treatment of diffuse skeletal metastases

Davood Beiki¹, Maryam Tajik¹, Peiman Haddad², Babak Fallahi¹,
Amir Mohammad Arefpour², Hamidreza Mirzaei³, Armaghan Fard-Esfahani¹,
Alireza Emami-Ardekani¹, Mohammad Eftekhari¹

¹Research Center for Nuclear Medicine, Tehran University of Medical Sciences, Tehran, Iran

²Department of Radiation Oncology, Cancer Research Center, Cancer Institute,
Tehran University of Medical Sciences, Tehran, Iran

³Radiation Oncology Department, Cancer Research Center, Shohada-e-Tajrish Hospital,
Shaheed Beheshti University of Medical Sciences, Tehran, Iran

(Received 13 June 2014, Revised 7 August 2014, Accepted 14 August 2014)

ABSTRACT

Introduction: Bone metastases are the most common cause of cancer-related pain in various primary malignant tumors, most often, breast and prostate. ^{188}Re -hydroxyethylidene diphosphonate (^{188}Re -HEDP) is a new and less expensive bone seeking radiopharmaceutical with favorable physical characteristics of the radionuclide such as short half life of 16.9h, maximal β energy of 2.1 MeV with a 15% γ -component of 155 keV and easily available from an in-house $^{188}\text{W}/^{188}\text{Re}$ generator. The aim of this study is to evaluate the therapeutic efficacy and safety profile of bone palliative therapy following administration of ^{188}Re -HEDP.

Methods: Twenty patients with painful metastatic bone lesions secondary to breast, prostate, multiple myeloma, ampulla of Vater and lung cancers received 1 mCi/kg of ^{188}Re -HEDP. Four hours after treatment, post-therapy scintigraphy was performed. All patients were interviewed using a standard set of questions (visual analogue scale: VAS) concerning their pain relief before, and after therapy at weekly intervals for the first month and every 2 weeks for the following 4 months. The general condition of the patients was also evaluated by Karnofsky-index and ECOG (Eastern Cooperative Oncology Group) performance status. Hematologic profiles were recorded before treatment and every two weeks up to 8 weeks after treatment.

Results: Overall pain relief was found in 68.8% of patients. Decreased from 8.37 ± 2.12 to 5.68 ± 2.98 at VAS was observed 4 weeks after treatment. The osteoblastic lesions (breast and prostate) showed rather similar response to the treatment. Mean platelet counts decreased in 6th week and returned to baseline level in 8th week. One patient showed grade III leukopenia without any serious complication.

Conclusion: ^{188}Re -HEDP is an effective radiopharmaceutical for metastatic bone pain palliation therapy. Side effects include mild and transient thrombocytopenia and leucopenia and no life threatening side effect is observed.

Key words: ^{188}Re -HEDP; Bone pain; Palliation therapy; Metastasis

Iran J Nucl Med 2015;23(1):44-48

Published: December, 2014

<http://irjnm.tums.ac.ir>

Corresponding author: Dr. Babak Fallahi, Research Center for Nuclear Medicine, Dr. Shariati Hospital, Tehran University of Medical Sciences, Tehran, Iran. E-mail: bfallahi@sina.tums.ac.ir

INTRODUCTION

Bone metastases are responsible for most of the morbidity and mortality associated with malignant tumors. It may be found in 70% of patients with prostate and breast cancer, and in up to 30% of the lung, bladder, or thyroid cancer [1, 2].

These metastases to bone are associated with skeletal-related events such as significant morbidity, loss of functional independence and reduction in quality of life. Bone metastases are often complicated by pain. It can be focal or multifocal, localized or diffuse, mild or severely disabling. The management of patients with metastatic bone pain must be a multidisciplinary approach and may include the use of analgesic drugs, external beam radiotherapy, surgery, chemotherapy, hormone treatment, systemic radionuclide therapy and administration of bisphosphonates. Pain palliation with bone seeking radiopharmaceuticals has been proven to be an effective treatment modality in patients with metastatic bone pain [1, 3]. A number of bone seeking radiopharmaceuticals have been tested and employed for this purpose. While all effective, there was no statistical significant difference between the various agents in terms of pain palliation, analgesic use, or bone marrow toxicity [4-6].

¹⁸⁸Re-hydroxyethylidene diphosphonate (¹⁸⁸Re-HEDP) is a new and less expensive bone seeking radiopharmaceutical with favorable physical characteristics such as short half life of 16.9h, maximal β energy of 2.1 MeV with a 15% γ -component of 155 keV. Its γ emission allows for bone metastases localization through imaging, making it both diagnostic and therapeutic. Re-188 is easily available from an in-house ¹⁸⁸W/¹⁸⁸Re generator which makes it convenient for clinical use especially when reactor-based radioisotopes such as Sm-153, Re-186, Lu-177 and Sr-89 are not available [1].

The aim of this study is to evaluate the therapeutic efficacy and safety profile of bone palliative therapy following administration of ¹⁸⁸Re-HEDP.

METHODS

Radiopharmaceutical

Re-188 was obtained from a commercially available ¹⁸⁸W/¹⁸⁸Re generator (ordered by AEOI, Iran). The ¹⁸⁸Re-HEDP was prepared according the previously published reports [7, 8].

Study population

The study was approved by the committee of ethics at Tehran University of Medical Sciences and all

patients gave written informed consent before therapy.

Twenty patients (10 men, 10 women; mean age, 57.1±13.8 years) with painful metastatic bone lesions were included in the study. The inclusion criteria were bone pain symptoms requiring the long-term use of analgesics, a recent positive bone scans with areas of abnormal increased radiotracer uptake corresponding to the sites of bone pain, life expectancy of at least 3 months, age of at least 18 years, normal renal function (creatinine <180 μ mol/l and/or GFR >30 ml/min), sufficient bone marrow function (haemoglobin >90 g l⁻¹, total white cell count >3.5×10⁹ l⁻¹ and platelet count >100×10⁹ l⁻¹) and the ability to understand and willingness to sign an informed consent document.

Patients with metastatic bone fractures, spinal cord compression, and soft tissue tumors elsewhere causing nerve compression were excluded. Other exclusion criteria were pregnant or breastfeeding women, patients with history of bisphosphonate therapy, chemotherapy or hemi-body external radiation therapy during 4-6 weeks before ablative therapy, clinically significant bleeding disorders, hypersensitivity to phosphonate compounds and those with evidence of acute or chronic renal failure.

Study measurements

All patients were interviewed before treatment and fill the questionnaire according to VAS score (visual analog scale) and analgesic dose intake in last 2 weeks. The general condition of patients was also assessed by karnofsky index and ECOG (Eastern Cooperative Oncology Group) performance status. A pain relief ≤ 2 scores on the VAS without increase of analgesic dose in the first 4 weeks after injection was defined as criteria for response. After hydration with 1 liter of saline, each patient received 1 mCi/Kg ¹⁸⁸Re-HEDP, intravenously. Anterior and posterior whole body images were obtained at 4h following injection using high energy collimator to reduce the effect of the bremsstrahlung to the image quality. A 10% window was centered at peak of 155 KeV.

Blood counts were obtained to evaluate the impairment at baseline and 2, 4, 6 and 8 weeks after radiopharmaceutical administration. Bone marrow suppression was graded according to the National Cancer Institute common toxicity criteria (NCI CTC version 2). Patients were followed at weekly intervals for the first month and every 2 weeks until 4 months. VAS score, analgesic dose, Karnofsky index and ECOG performance status were recorded at all time intervals. For narcotic drugs we calculated oral morphine dose equivalent. Data analysis was performed using SPSS 17 software. Quantitative variables in paired samples (different time points) were analyzed by General Linear Model (GLM)

repeated measures. P values < 0.05 were considered as significant.

RESULTS

Twenty patients (10 men, 10 women; mean age, 57.1±13.8 years) were entered the study. Of these patients, 10 had breast cancer, 7 with prostate cancer, 1 multiple myeloma, 1 lung cancer and 1 adenocarcinoma of ampulla of vater. Eighteen patients (90%) had a history of systemic chemotherapy and 14 patients (70%) received radiotherapy at least 1 month before ¹⁸⁸Re-HEDP administration. Fifteen patients (75%) were under bisphosphonate therapy (pamidronate and zoledronic acid) which was discontinued at least 4 weeks before radiopharmaceutical treatment.

Six patients (30%) reported worsening of pain during the first week after injection (flare phenomenon). Four patients increased their analgesic intake in the first four weeks, so they were not included in the pain relief response calculation. In the rest of the patients, overall pain relief response was 68.8%. The VAS scores showed a decrease from second week after therapy (6.87±2.33 vs. 8.37±2.12; p=0.002). The maximum pain relief was described in the 4th week following the treatment (5.68±2.98; p=0.001). Even at the 16th weeks VAS scores were significantly lower than baseline (6.31±3.32 vs. 8.37±2.12; p=0.017) (Figure 1).

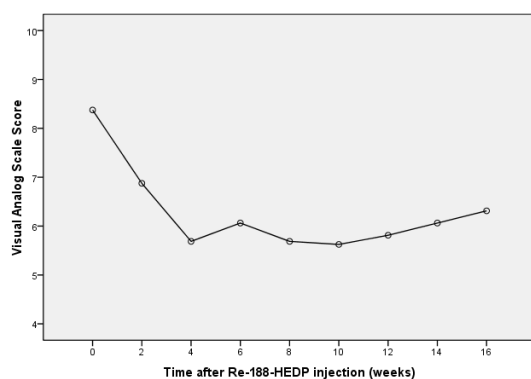


Fig 1. The pain VAS scores at baseline and within 16 weeks after ¹⁸⁸Re-HEDP therapy.

The Karnofsky and ECOG performance scales showed no significant changes after therapy (p=0.190 for ECOG and P=0.60 for Karnofsky). Mean analgesic and narcotic intake dose didn't show any significant changes until 16th weeks after ¹⁸⁸Re-HEDP injection (p=0.33 for analgesics and p=0.51 for narcotics).

Mean platelet counts decreased in 6th week ($176 \times 10^3 \pm 76 \times 10^3/\text{ml}$ vs. $255 \times 10^3 \pm 81 \times 10^3/\text{ml}$ at baseline; p=0.02) and returned to baseline level in 8th week ($214 \times 10^3 \pm 54 \times 10^3/\text{ml}$). Many of patients had anemia before ¹⁸⁸Re-HEDP injection with no significant worsening during the study. Mean leukocyte counts in 6th week were significantly lower than baseline ($4853 \pm 2190/\text{ml}$ vs. $6515 \pm 2340/\text{ml}$; p=0.02). according to common toxicity criteria version 4, one patient showed grade III thrombocytopenia and one patient grade III leukopenia without any serious complication. Figure 2 shows ¹⁸⁸Re-HEDP scan of an 81 year old man with multiple bone metastases of prostate cancer.

DISCUSSION

Bone metastases are a common manifestation of malignancy that can cause significant morbidity. Systemic therapy using bone-seeking radiopharmaceuticals has clear advantages for the treatment of multisite metastatic pain [9]. A great number of studies using bone-seeking radiopharmaceuticals for the palliation of painful bone metastases have been published. Requirements for an optimal therapeutic radionuclide agent for the palliation of painful bone metastases are selective uptake, prolonged retention at metastatic sites and rapid clearance from soft tissues or normal bone. The predictable biodistribution of bone scan, a simple production process, radiochemical stability, easily transportable, readily available with good distributor logistics, cost effectiveness, lack of toxicity, radiation safety, and acceptable specifications are among the characteristics of a desirable palliative radionuclide.

¹⁸⁶Re-HEDP, ¹⁵³Sm-EDTMP and ¹⁷⁷Lu-EDTMP have been available in Iran in recent years [10-13]. However, limitations such as reduction of nuclear fuel in Tehran Research Nuclear Reactor due to imposed sanctions as well as limited reports on efficacy of bone pain palliation therapy by ¹⁸⁸Re-HEDP were our main reasons to design the current study in order to use an onsite ¹⁸⁸W/¹⁸⁸Re generator independent of reactor production and examine the efficacy of ¹⁸⁸Re-HEDP in palliation of bone pain.

According to the study by Palmedo et al [8] the maximum administered dose was 90 mCi if the baseline platelet count was below $200 \times 10^3/\text{ml}$, and 120 mCi if it was above $200 \times 10^3/\text{ml}$.

To avoid the confounding effect of analgesics on bone pain relief, we excluded the patients who increased their analgesic dose (4 patients). In the current study, the response rate was 68.8% that is comparable with other studies by Palmedo et al (64%) [8], Liang et al (73.3%) [14] and Cheng et al (73.3%) [15].

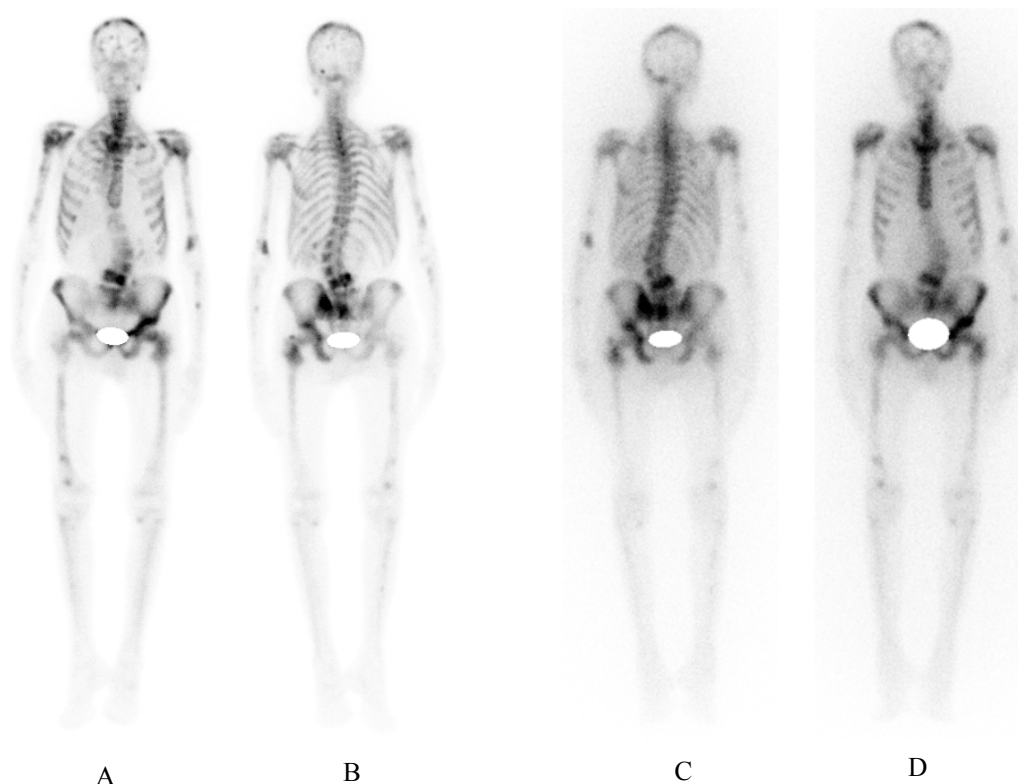


Fig 2. (A) Anterior and (B) posterior projections of the ^{99m}Tc-MDP bone scan of an 81 year old man with multiple bone metastases of prostate cancer. (C) Posterior and (D) anterior views of ¹⁸⁸Re-HEDP scan for the same patient.

In other studies like Liepe et al [16, 17], Li et al [18], Biersack et al [19] and Zhang et al [20], better overall pain response are reported in comparison to our study. Different definition of pain palliation response or possible confounding effect of analgesics might be the explanation.

We observed no difference in response rate between two common breast and prostate osteoblastic metastatic lesions (80% in breast cancer, 60% in prostate cancer; $p=0.60$). Li et al [18] reported 80% response rate in prostate cancer and 83% in breast carcinoma.

In our study, pain relief began from the second week after injection and pain score showed a maximum decrease from 8.37 ± 2.12 to 5.68 ± 2.98 in the fourth week ($p=0.001$).

ECOG and Karnofsky performance status had no significant changes after ¹⁸⁸Re-HEDP administration. Liepe et al [16, 17] described significant improvement on the Karnofsky performance status after therapy in their studies. This finding however, was not confirming in another study [5]. This discrepancy may be due to cultural differences and more dependence on family members as was the case in our study. We recommended another study with

larger sample size for better evaluation of the effect of ¹⁸⁸Re-HEDP on patient's general condition.

Unlike previous studies, we did not observe any significant change in analgesic consumption. This may be due to chronic dependence on narcotics or small sample size of our study.

In our study, no unexpected complication was observed. There was one patient with grade III thrombocytopenia who had super scan pattern on bone scan and a previous history of Sr-89 injection 8 months before. We also did not encounter with any unpredictable adverse reaction during the cause of the study.

CONCLUSION

¹⁸⁸Re-HEDP demonstrated efficacy with acceptable toxicity when used to treat symptomatic, predominantly osteoblastic metastatic bone lesions.

Acknowledgements

This study was part of a MD thesis and financially supported by Tehran University of Medical Sciences (grant no. 14174). The authors declare that they have no conflicts of interest.

REFERENCES

1. Finlay IG, Mason MD, Shelley M. Radioisotopes for the palliation of metastatic bone cancer: a systematic review. *Lancet Oncol*. 2005 Jun;6(6):392-400.
2. Chiacchio S, Mazzarri S, Lorenzoni A, Nyakale N, Boni G, Borsò E, Alsharif A, Grosso M, Manca G, Greco C, Volterrani D, Mariani G. Radionuclide therapy and integrated protocols for bone metastases. *Q J Nucl Med Mol Imaging*. 2011 Aug;55(4):431-47.
3. Lam MG, de Klerk JM, van Rijk PP, Zonnenberg BA. Bone seeking radiopharmaceuticals for palliation of pain in cancer patients with osseous metastases. *Anticancer Agents Med Chem*. 2007 Jul;7(4):381-97.
4. Liepe K, Runge R, Kotzerke J. The benefit of bone-seeking radiopharmaceuticals in the treatment of metastatic bone pain. *J Cancer Res Clin Oncol*. 2005 Jan;131(1):60-6.
5. Liepe K, Kotzerke J. A comparative study of ¹⁸⁸Re-HEDP, ¹⁸⁶Re-HEDP, ¹⁵³Sm-EDTMP and ⁸⁹Sr in the treatment of painful skeletal metastases. *Nucl Med Commun*. 2007 Aug;28(8):623-30.
6. Baczyk M, Czepczyński R, Milecki P, Pisarek M, Oleksa R, Sowiński J. ⁸⁹Sr versus ¹⁵³Sm-EDTMP: comparison of treatment efficacy of painful bone metastases in prostate and breast carcinoma. *Nucl Med Commun*. 2007 Apr;28(4):245-50.
7. Lin WY, Lin CP, Yeh SJ, Hsieh BT, Tsai ZT, Ting G, Yen TC, Wang SJ, Knapp FF Jr, Stabin MG. Rhenium-188 hydroxyethylidene diphosphonate: a new generator-produced radiotherapeutic drug of potential value for the treatment of bone metastases. *Eur J Nucl Med*. 1997 Jun;24(6):590-5.
8. Palmedo H, Guhlke S, Bender H, Sartor J, Schoeneich G, Risse J, Grünwald F, Knapp FF Jr, Biersack HJ. Dose escalation study with rhenium-188 hydroxyethylidene diphosphonate in prostate cancer patients with osseous metastases. *Eur J Nucl Med*. 2000 Feb;27(2):123-30.
9. Lewington VJ. Bone-seeking radionuclides for therapy. *J Nucl Med*. 2005 Jan;46 Suppl 1:38S-47S.
10. Pirayesh E, Amoui M, Mirzaee HR, Tabei F, Rakhsha A, Kalantari BA, Shafiei B, Assadi M, Asli IN. Phase 2 study of a high dose of ¹⁸⁶Re-HEDP for bone pain palliation in patients with widespread skeletal metastases. *J Nucl Med Technol*. 2013 Sep;41(3):192-6.
11. Beiki D, Haddad P, Fallahi B, Keyvan A, Gholamrezanezhad A, Mirzaei H, Saghari M, Amouzegar-Hashemi F, Kazemian A, Fard-Esfahani A, Eftekhari M. Effectiveness and complications of ¹⁵³Sm-EDTMP in palliative treatment of diffuse skeletal metastases. *Iran J Nucl Med*. 2013;21(1):26-32.
12. Bahrami-Samani A, Ghannadi-Maragheh M, Jalilian AR, Shirvani-Arani S, Meftahi M, Moradkhani S. Production, quality control and biological evaluation of ¹⁵³Sm-EDTMP in wild-type rodents. *Iran J Nucl Med*. 2009;17(2):12-19.
13. Bahrami-Samani A, Anvarib A, Jalilian AR, Shirvani-Arani S, Yousefnia H, Aghamiri MR, Ghannadi-Maragheh M. Production, quality control and pharmacokinetic studies of ¹⁷⁷Lu-EDTMP for human bone pain palliation therapy trials. *Iran J Pharm Res*. 2012;11(1):137-144.
14. Liang JG, Jiang NY, DU JQ, Lu XP, Liu XG, Chen SX. Clinical value of combined therapy with ¹⁸⁸Re-HEDP and pamidronate in breast cancer with bone metastasis. *Zhonghua Zhong Liu Za Zhi*. 2005 Mar;27(3):180-2.
15. Cheng A, Chen S, Zhang Y, Yin D, Dong M. The tolerance and therapeutic efficacy of rhenium-188 hydroxyethylidene diphosphonate in advanced cancer patients with painful osseous metastases. *Cancer Biother Radiopharm*. 2011 Apr;26(2):237-44.
16. Liepe K, Franke WG, Kropp J, Koch R, Runge R, Hliscs R. Comparison of rhenium-188, rhenium-186-HEDP and strontium-89 in palliation of painful bone metastases. *Nuklearmedizin*. 2000 Sep;39(6):146-51.
17. Liepe K, Kropp J, Runge R, Kotzerke J. Therapeutic efficiency of rhenium-188-HEDP in human prostate cancer skeletal metastases. *Br J Cancer*. 2003 Aug 18;89(4):625-9.
18. Li S, Liu J, Zhang H, Tian M, Wang J, Zheng X. Rhenium-188 HEDP to treat painful bone metastases. *Clin Nucl Med*. 2001 Nov;26(11):919-22.
19. Biersack HJ, Palmedo H, Andris A, Rogenhofer S, Knapp FF, Guhlke S, Ezziddin S, Bucerius J, von Mallek D. Palliation and survival after repeated (¹⁸⁸Re)-HEDP therapy of hormone-refractory bone metastases of prostate cancer: a retrospective analysis. *J Nucl Med*. 2011 Nov;52(11):1721-6.
20. Zhang H, Tian M, Li S, Liu J, Tanada S, Endo K. Rhenium-188-HEDP therapy for the palliation of pain due to osseous metastases in lung cancer patients. *Cancer Biother Radiopharm*. 2003 Oct;18(5):719-26.