

Surgical Management versus Spontaneous Resorption of Congenital Membranous Cataracts

Mehrdad Mohammadpour, MD¹ • Mostafa Mafi, MD²
Mahmoud Jabbarvand, MD³ • Hassan Hashemi, MD⁴

Abstract

Purpose: To report a rare case of spontaneous resorption of a membranous congenital cataract in an adult woman with no systemic disease, with complete absorption of the central lens material, anterior and posterior capsules of the right eye, and partial absorption of the lens material with intact anterior capsule in the left eye.

Case report: A 23-year-old woman was referred to our clinic suffering from decreased vision from childhood. Her visual acuity (VA) was $1/10$ in the right eye (OD) and FC (40 cm) in the left eye (OS) after correction with +10.25 spherical Diopter in both eyes (OU). Her ocular history revealed profound low vision and nystagmus from childhood, with no prior intervention in either eye. The slit examination of the right eye revealed white opaque membranes at the periphery of the lens which were presumably remnants of the lens capsule. The central lens material was completely absorbed as well as anterior and posterior capsules, mimicking a surgical anterior and posterior capsulorrhexis. The left eye examination showed membranous cataract presenting as a piece of dense white fibrotic membrane and small amount of residual cortex at the peripheral part. The chalky-white lens material was partially absorbed with intact anterior capsule.

Conclusion: As complete spontaneous resorption of membranous congenital cataracts leading to high refractive hyperopia and amblyopia may happen in children with congenital cataracts, careful ocular examinations seems to be essential to avoid neglecting comorbid pathologies specially in children with high refractive errors and/or amblyopia. Surgical management of membranous cataracts need special considerations.

Keywords: Congenital, Membranous, Cataract

Iranian Journal of Ophthalmology 2012;24(3):65-68 © 2012 by the Iranian Society of Ophthalmology

-
1. Assistant Professor of Ophthalmology, Cornea Specialist, Eye Research Center, Farabi Eye Hospital, Tehran University of Medical Sciences, Tehran, Iran
 2. Resident in Ophthalmology, Eye Research Center, Farabi Eye Hospital, Tehran University of Medical Sciences, Tehran, Iran
 3. Professor of Ophthalmology, Eye Research Center, Farabi Eye Hospital, Tehran University of Medical Sciences, Tehran, Iran
 4. Noor Ophthalmology Research Center, Noor Eye Hospital - Professor of Ophthalmology, Eye Research Center, Farabi Eye Hospital, Tehran University of Medical Sciences, Tehran, Iran

Received: February 15, 2012

Accepted: August 9, 2012

Correspondence to: Mehrdad Mohammadpour, MD

Assistant Professor of Ophthalmology, Cornea Specialist, Eye Research Center, Farabi Eye Hospital, Tehran University of Medical Sciences, Tehran, Iran, Email: mahammadpour@yahoo.com

Disclosure: There is no financial interest for the authors in any methods or materials mentioned in this article.

Introduction

As a common treatable etiology of childhood blindness, congenital cataracts present with unilateral or bilateral lens opacity at or soon after birth.¹ Intrauterine infections, systemic diseases, or autosomal heritability are known causes while many are found to be idiopathic.¹ Membranous cataract is a mostly sporadic, bilateral and rare subtype characterized by a flattened and collapsed capsule with diminished cortex or epithelium on the lens which results in severe visual disturbances.² Intrauterine iridocyclitis, aniridia and corneal opacification; glaucoma, microphthalmia and a variety of systemic disorders are described in association with the disease.²⁻⁴ Yet spontaneous resorption of congenital cataracts has been reported infrequently. Here in, we describe a neglected unusual case of spontaneous resorption of a membranous congenital cataract in an adult woman, with complete absorption of the central lens material, anterior and posterior capsules of the right eye, mimicking a surgical anterior and posterior capsulorrhexis and partial absorption of the lens material with intact anterior capsule in the left eye.

Case report

A 23-year-old woman was referred to our clinic suffering from decreased vision from childhood. Her past medical history and systemic examination revealed no systemic disease. There was no history of cataract in other siblings or in the patients' family. There was no paraclinic examinations to rule out TORCH when she was a newborn baby, however, at this age (23 years old) performing serologic tests was not judicious. Her visual acuity (VA) was $1/10$ in the right eye (OD) and FC (40 cm) in the left eye (OS) after correction with +10.25 spherical Diopter in both eyes (OU). Her ocular history revealed profound low vision and nystagmus from childhood, with no prior intervention in either eye. The intraocular pressure (IOP) in both eyes measured 16 mmHg by Goldmann applanation tonometer.

The examination of the right eye revealed white opaque membranes at the periphery of the lens which were presumably remnants of the lens capsule (Figure 1). The central lens material was completely absorbed as well as anterior and posterior capsules, mimicking a

surgical anterior and posterior capsulorrhexis. This could be explained by spontaneous resorption of the congenital cataract of the right eye which led to deletion of the central dense opaque membrane and formation of remnants of these membranes at the periphery. This process also explains the better corrected visual acuity (BCVA) of the right eye of the patient.

The left eye examination showed membranous like cataract as a piece of dense white fibrotic membrane and small amount of residual cortex at the peripheral part. The chalky-white lens material was partially absorbed with intact anterior capsule (Figure 2).

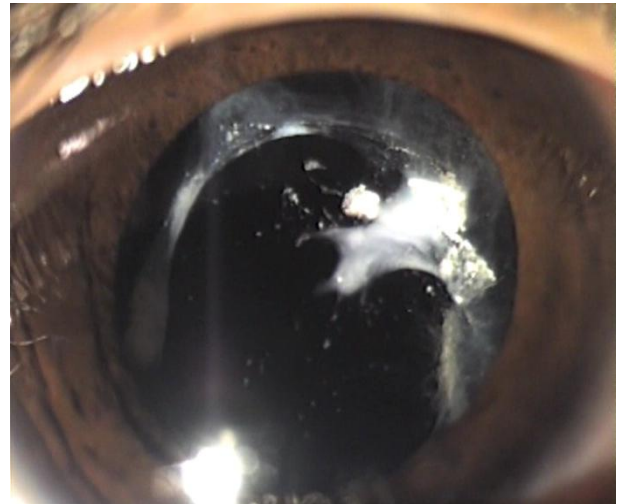


Figure 1. The right eye with complete resorption of membranous cataract mimicking surgical capsulorrhexis, anterior lensectomy and anterior vitrectomy

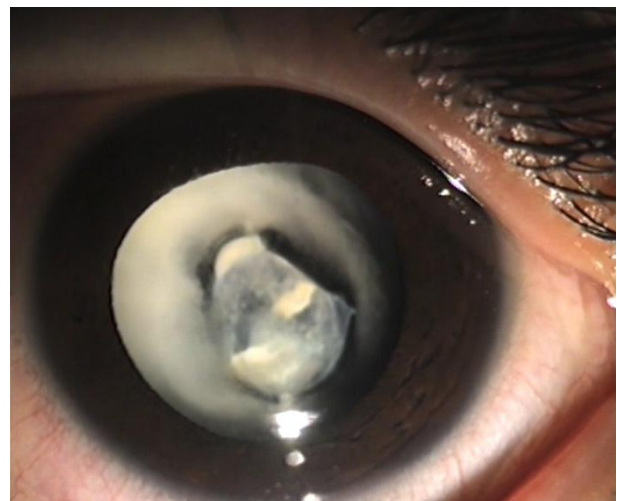

Figure 2. The left eye with partial resorption of membranous cataract

The axial length of left eye measured 25.15 mm. The right eye was planned for secondary IOL implantation, however, due to socioeconomic problems and inability to stay for consequential surgery, the patient wanted the surgery to be done only on the left eye, and postponed the right eye surgery. The left eye underwent anterior lensectomy and vitrectomy and posterior chamber intraocular lens implantation with IOL power of 15.00 Diopters.

Discussion

Membranous cataract, a bilateral and rare subtype of congenital cataracts, is characterized by a flattened and collapsed capsule with diminished cortex or epithelium on the lens which results in severe visual disturbances.² The etiology of development of membranous cataract remains unclear. Intrauterine inflammation or infection such as maternal rubella have been described as possible etiologies.² Lens capsule rupture and absorption of the cortex due to failure of separation of the lens vesicle from the surface epithelium in embryonic stage has been hypothesized which could lead to complete absorption of the crystalline lens in some cases.²

Although there are reports about spontaneous cataract resorption in animals,^{5,6} spontaneous reduction and absorption of congenital cataracts in human has been reported infrequently.⁷ This phenomenon has been described in 8 percent of cases with Hallermann-Streiff-syndrome; a syndrome with various systemic manifestations such as frontal prominence, progeria, micrognathia and hypodontia and ocular features including blue sclera, bilateral microphthalmia and strabismus. Cataract, as a major ocular feature occurs in 90% of cases.⁸

Congenital cataracts needs special attention in terms of surgical problem such as extending capsulorrhexis, choosing type of

IOL and postoperative inflammation specially in young cases.⁹⁻¹⁴

There are many known etiologic factors such as physical environmental hazards that may cause changes in the permeability of the anterior capsule leading to cataracts.¹⁵ However, the exact mechanism of the congenital cataracts has not been explained.

To the best of our knowledge, there have been no published reports to date of complete spontaneous resorption of membranous congenital cataract in an adult with no systemic disease. In our reported case, there was complete central absorption of anterior and posterior capsules and lens materials mimicking surgical anterior and posterior capsulorrhexis and anterior lensectomy and vitrectomy. Such a complete resorption of lens material led to relative restoration of vision at the patients' right eye in comparison to her fellow eye. [$1/_{10}$ vs. FC (40 cm) after correction]. As a probable explanation for this phenomenon, eye rubbing by patient due to low vision can superimpose low capsular integrity and abnormal capsular functioning of lens material leading to microperforation of anterior and posterior capsules and leakage of lens material to anterior chamber or vitreous cavity, respectively and complete resorption of lens material.

Conclusion

To the best of our knowledge, this is the first reported case of complete spontaneous resorption of membranous congenital cataracts with complete resorption of the central part of the cataract and fusion of peripheral anterior and posterior capsules mimicking a surgical lensectomy and anterior vitrectomy in one eye and partial absorption of the cataract in the fellow eye leading to high refractive hyperopia and amyopia. Careful ocular examination seems to be essential to avoid neglecting comorbid pathologies like cataracts.

References

1. Merin S, Crawford JS. The etiology of congenital cataracts. A survey of 386 cases. *Can J Ophthalmol* 1971;6(3):178-82.
2. Mirdehghan SA, Dehghan MH, Mohammadpour M, et al. Causes of severe visual impairment and blindness in schools for visually handicapped children in Iran. *Br J Ophthalmol* 2005;89(5):612-4.
3. Yoshikawa K, Asakage H, Inoue Y. Membranous cataract in association with aniridia. *Jpn J Ophthalmol* 1993;37(3):325-9.
4. Agarwal LP, Ralizada IN. Congenital membranous cataract, dentigerous cyst, and multiple fibrolipomata. *Br J Ophthalmol* 1954;38(6):383-5.
5. Ofri R, Horowitz I. Spontaneous cataract resorption in an ostrich. *Vet Rec* 1995;136(11):276.
6. Gonzalez-Alonso-Alegre E, Rodriguez-Alvaro A. Spontaneous resorption of a diabetic cataract in a geriatric dog. *J Small Anim Pract* 2005;46(8):406-8.
7. Krásný J, Kuchynka P, Lomícková H, Sach J. [Spontaneous reduction and absorption of cataracts in childhood]. *Cesk Slov Oftalmol* 2002;58(5):298-306.
8. Soriano JM, Funk J. [Spontaneous bilateral lens resorption in a case of Hallermann-Streiff syndrome]. *Klin Monbl Augenheilkd* 1991;199(3):195-8.
9. Mohammadpour M. Pediatric anterior capsulotomy preferences of cataract surgeons worldwide. *J Cataract Refract Surg* 2007;33(11):1838.
10. Mohammadpour M. Four-incision capsulorhexis in pediatric cataract surgery. *J Cataract Refract Surg*. 2007;33(7):1155-7.
11. Mohammadpour M. Management of radial tears during capsulorhexis. *Techniques in Ophthalmology* 2006;4(2):56-59.
12. Mohammadpour M. Rescue of an extending capsulorhexis by creating a midway tangential anterior capsular flap: a novel technique in 22 eyes. *Can J Ophthalmol* 2010;45(3):256-8.
13. Mohammadpour M, Erfanian R, Karimi N. Capsulorhexis: pearls and pitfalls. *Saudi Journal of Ophthalmology* 2012;26(1):33-40
14. Mohammadpour M, Jafarinasab MR, Javadi MA. Outcomes of acute postoperative inflammation after cataract surgery. *Eur J Ophthalmol* 2007;17(1):20-8.
15. Hashemi H, Jabbarvand M, Mohammadpour M. Bilateral electric cataracts: clinicopathologic report. *J Cataract Refract Surg* 2008;34(8):1409-12.